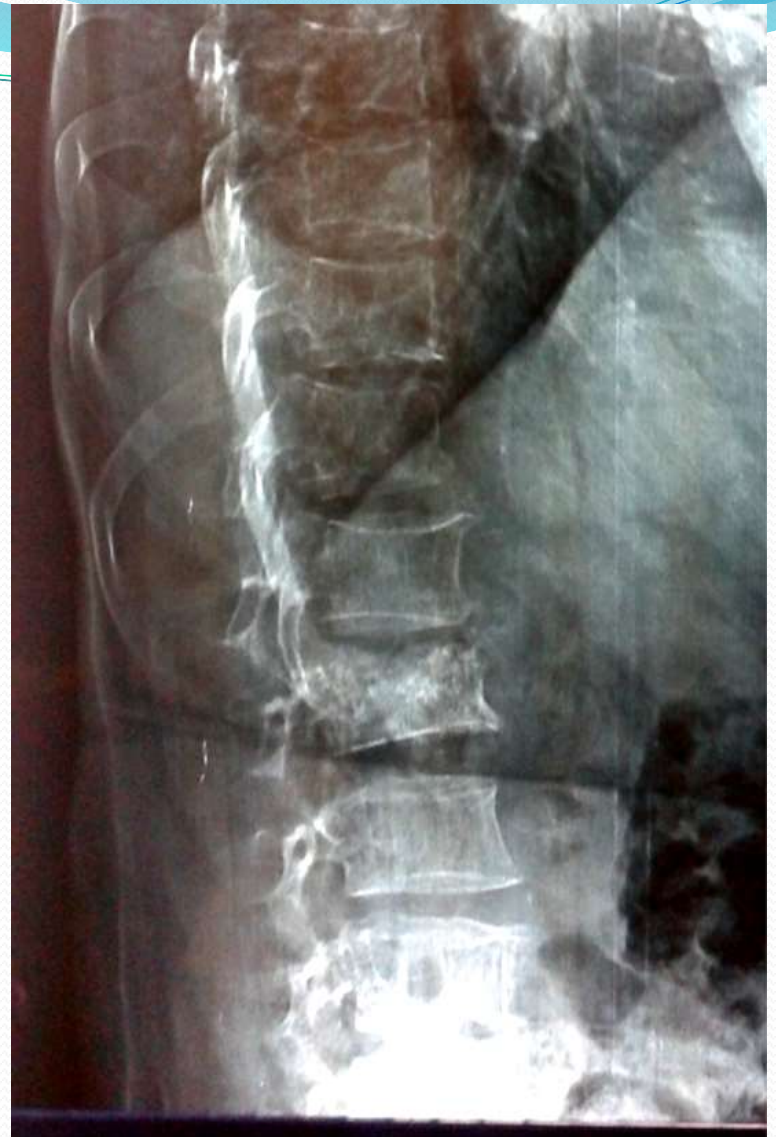
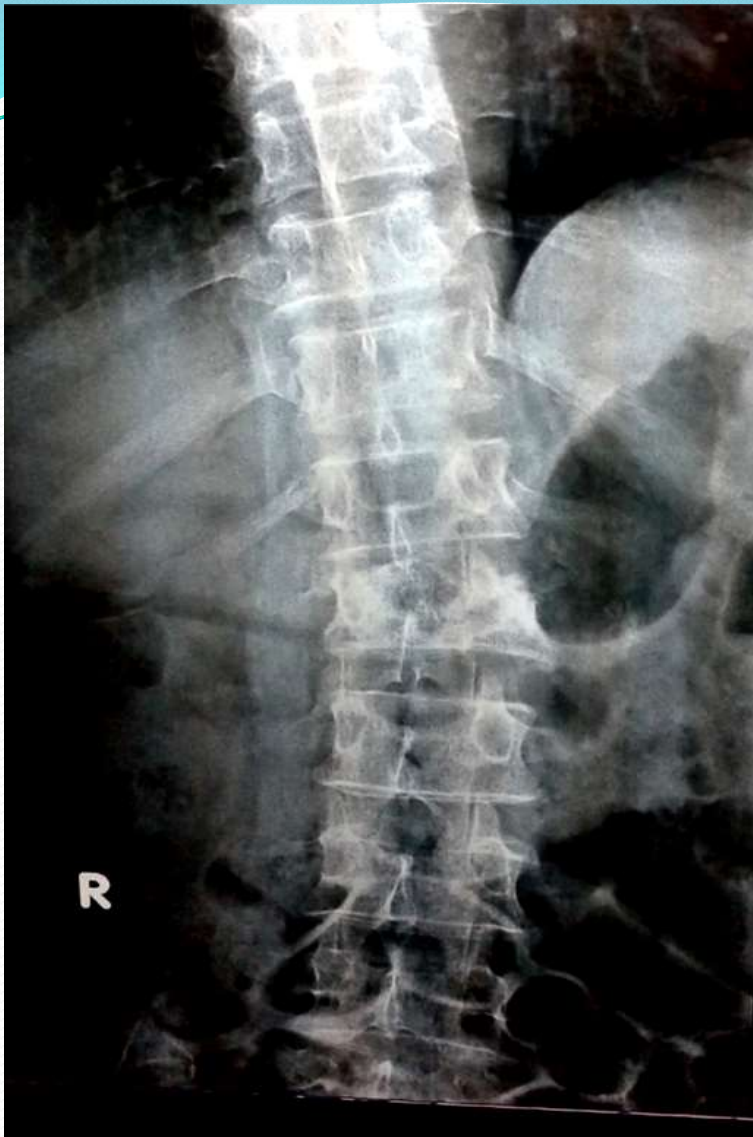
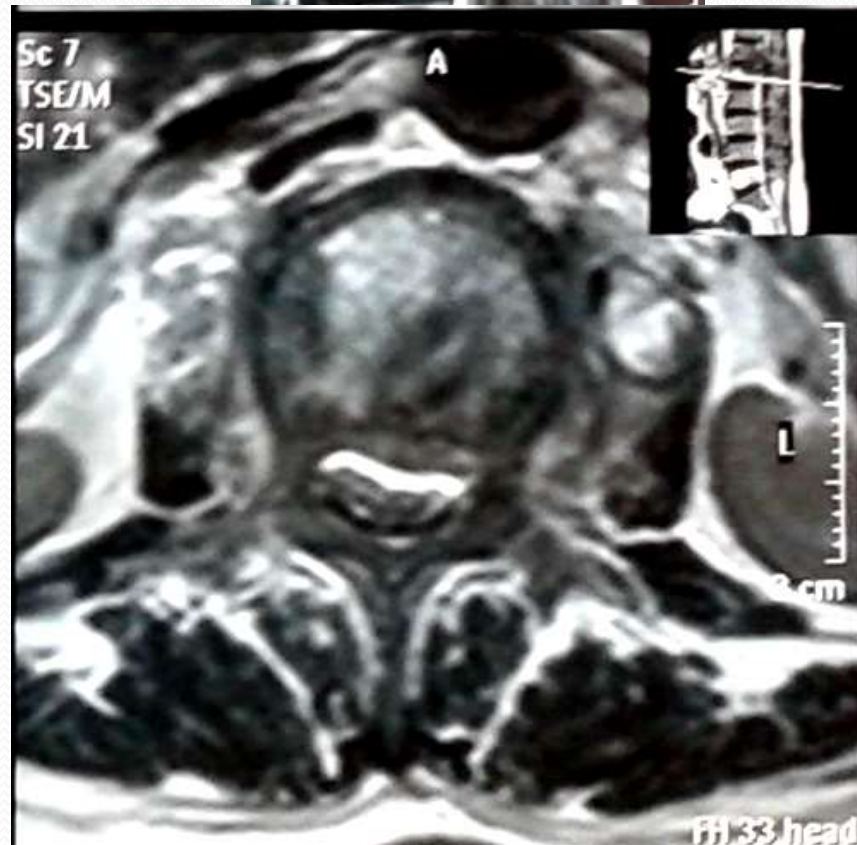
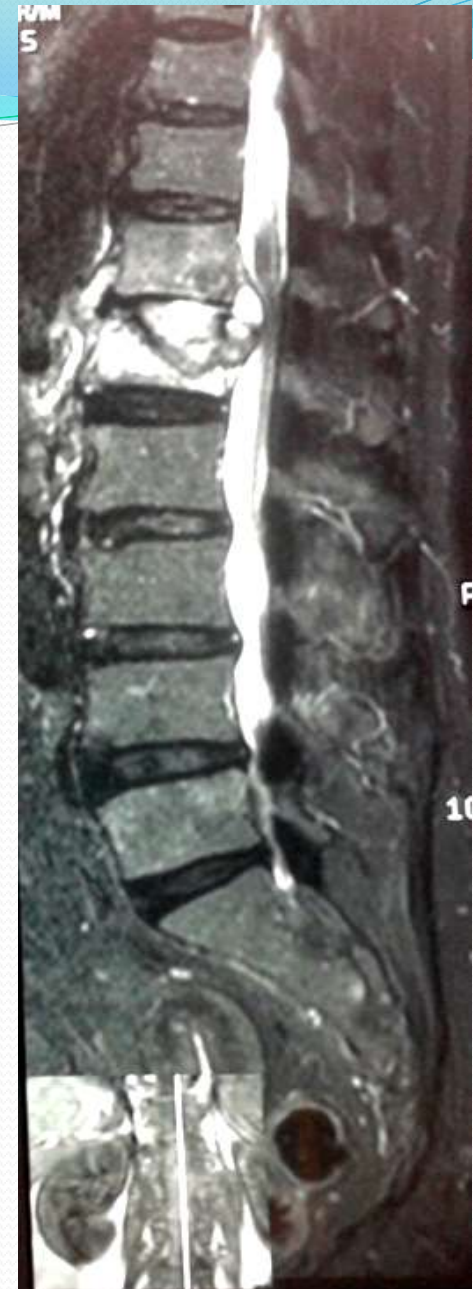
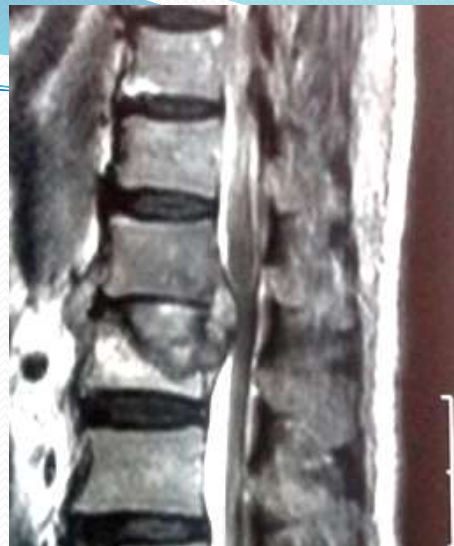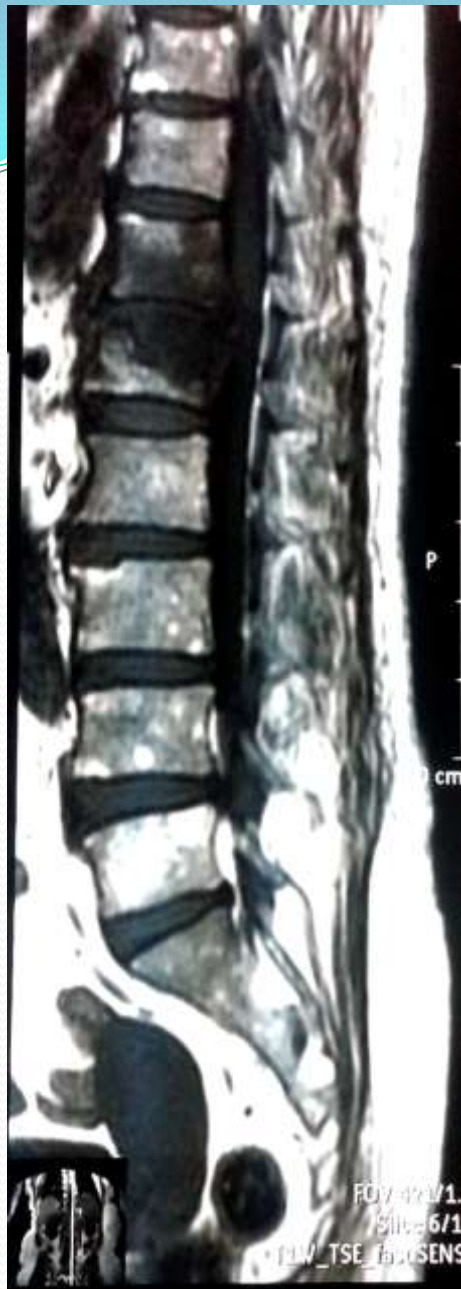Dr. Ahmed Saleh



55 y old lady, sever back pain, n. free



- CBC
 - HGB: 9.5
 - WBCS: normal
- ESR
 - 1st Hour: 65
- CRP : +ve

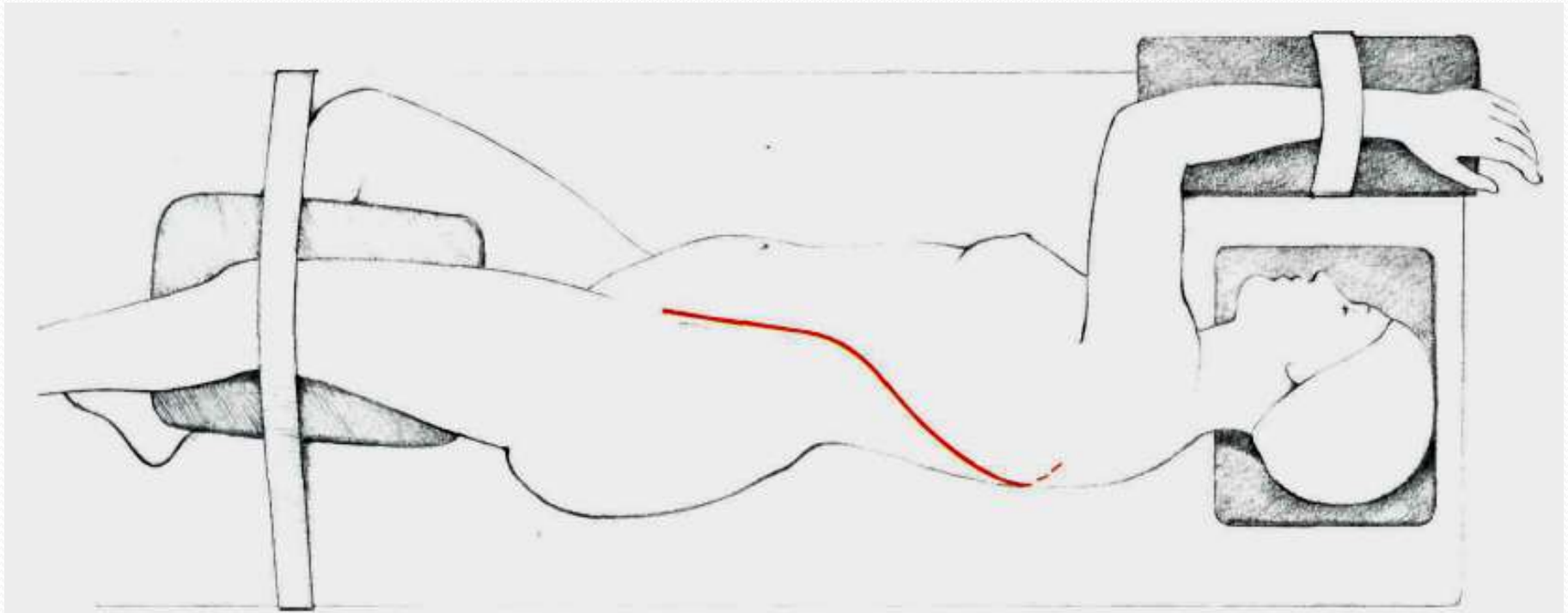


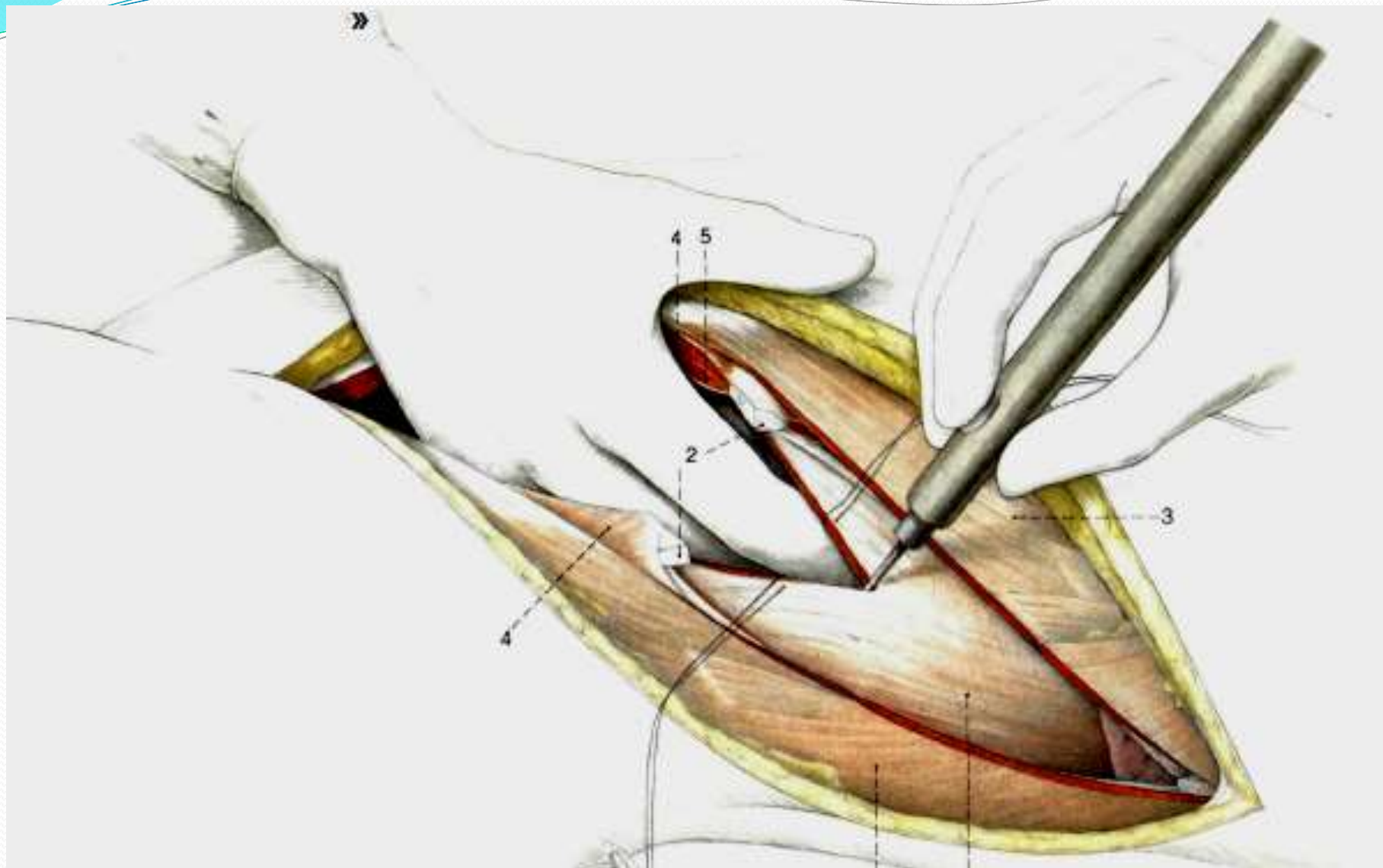
Diagnosis

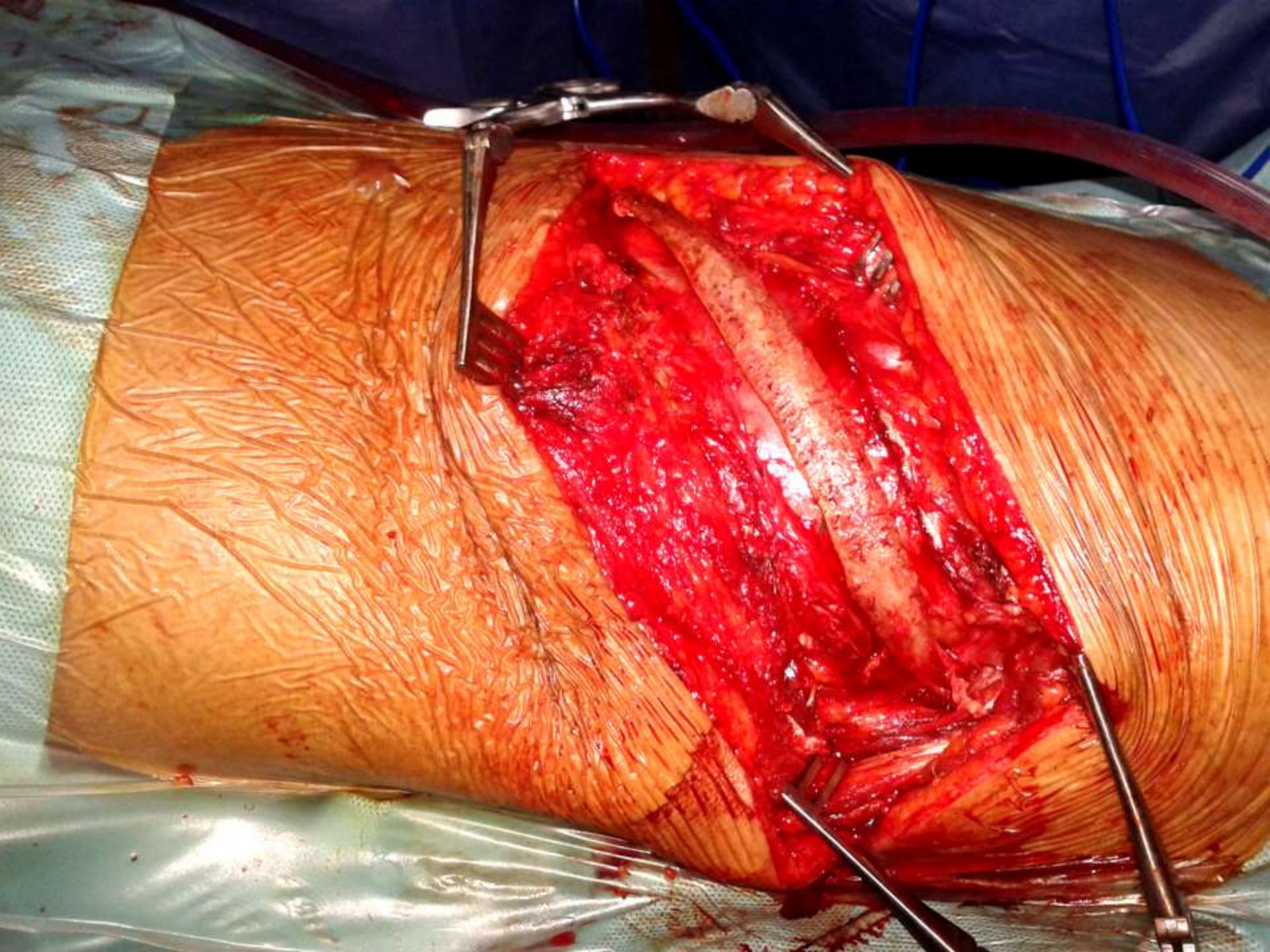

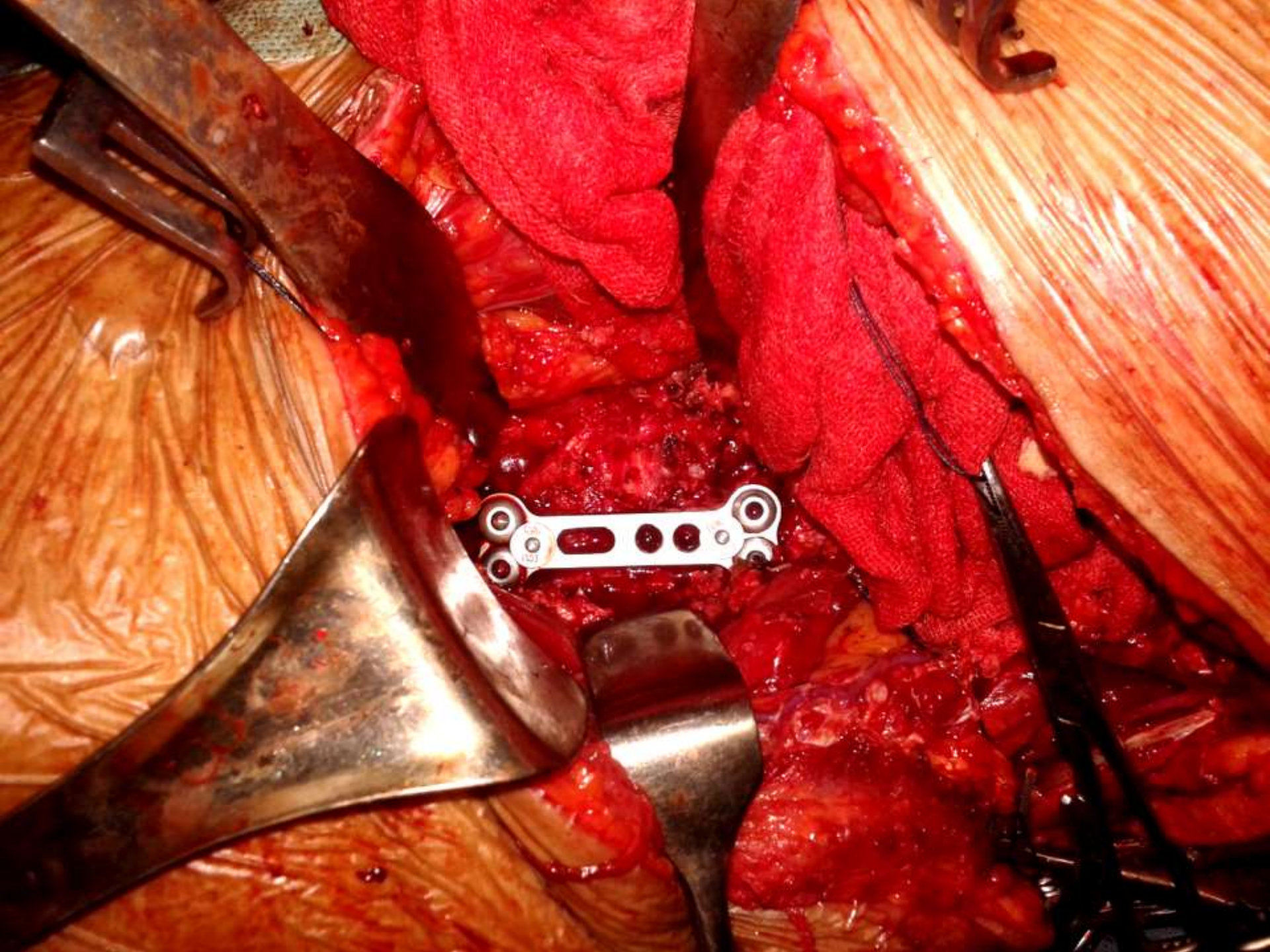
Approach: Anterior X Posterior

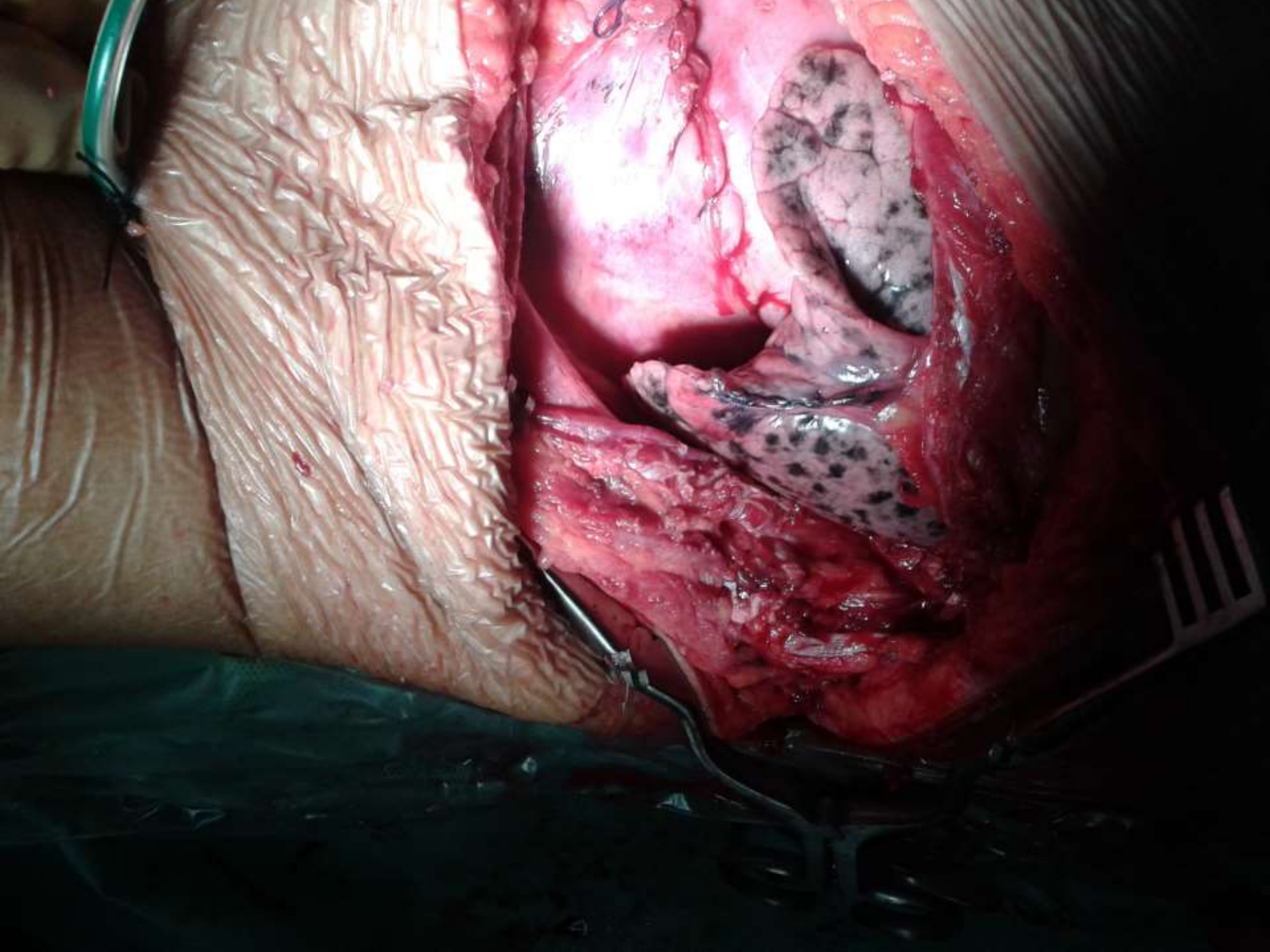Transpleural-Retroperitoneal app. (Hodgson)

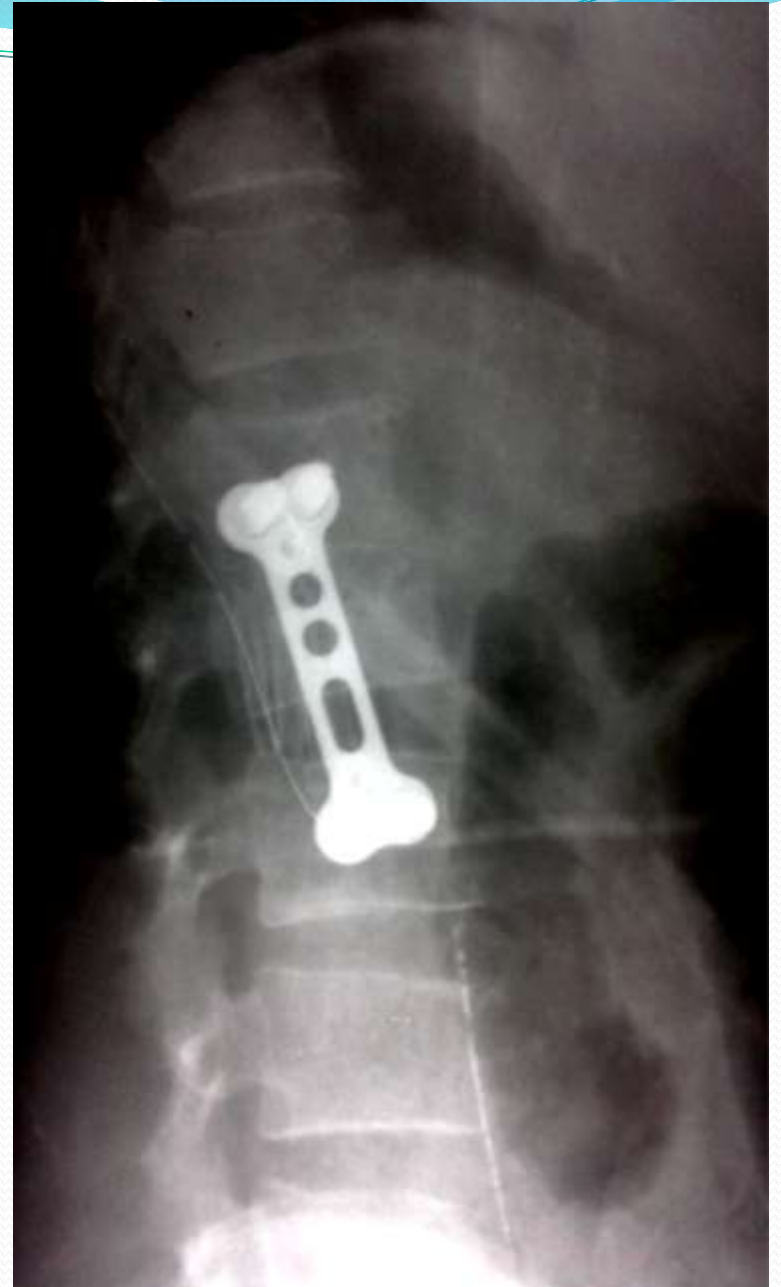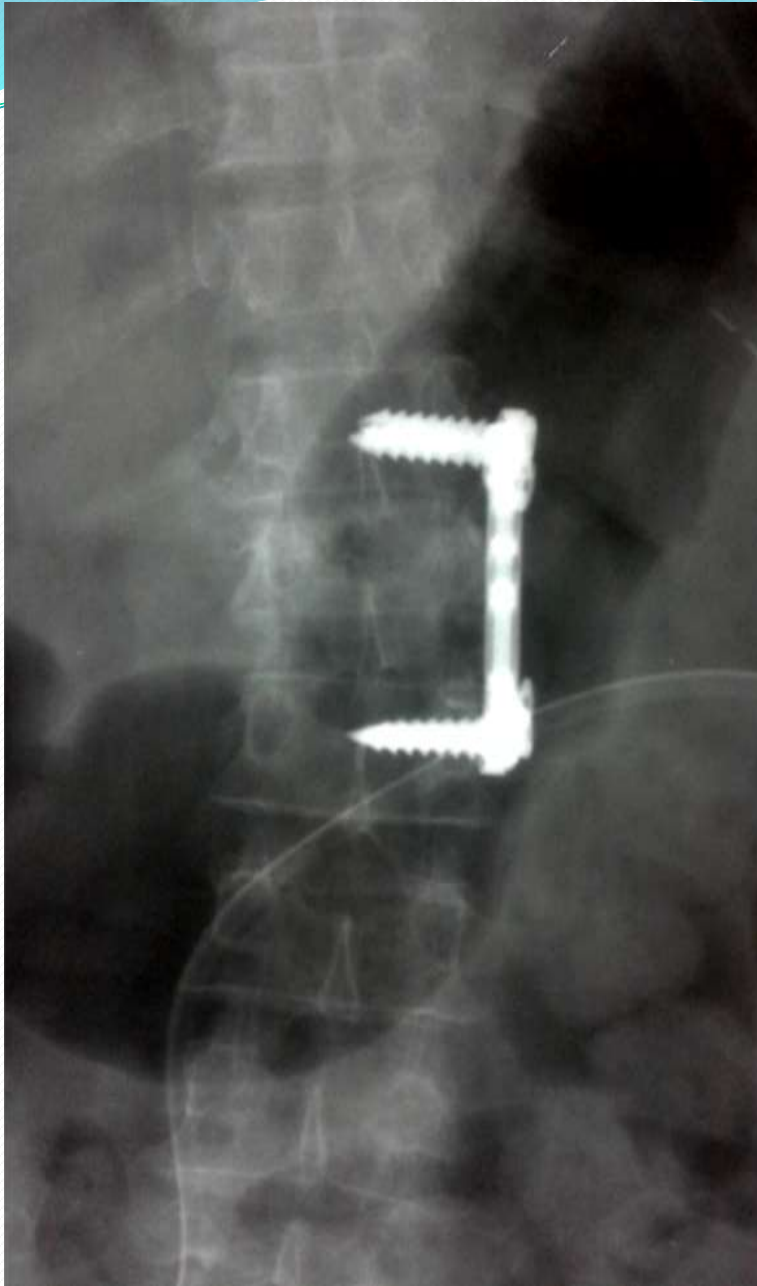







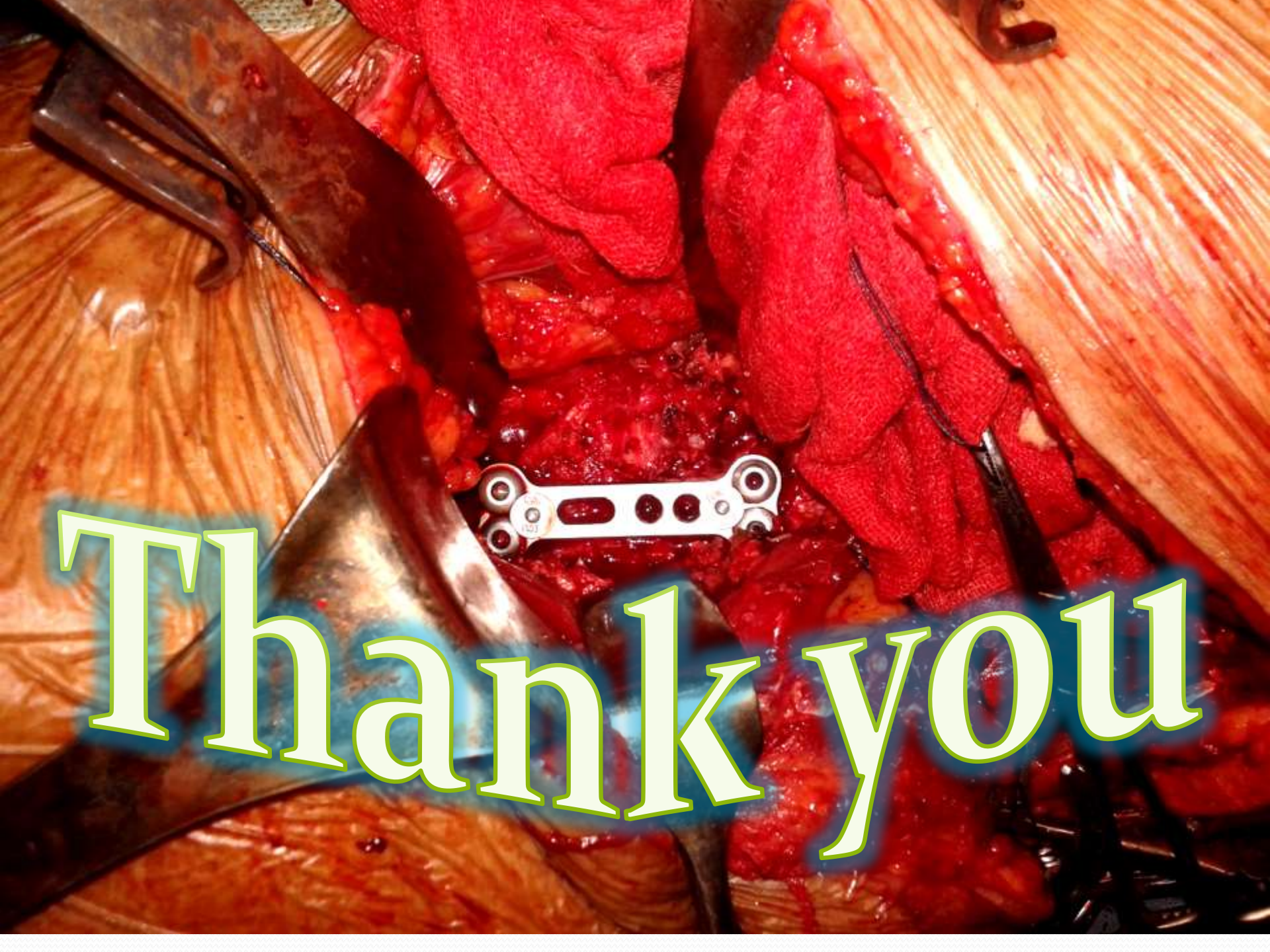




Surgical Tips

1. Take care of pleural adhesions.
2. Marking sutures in the diaphragm during splitting.
3. Retoperitoneal suction drain & intercostal tube.



Thank you